

eakin **Cohesive**[®] stomawrap with bulky, prolapsed stomas



A SMALL PART
OF A BIGGER LIFE.

Background

- 72 year old man
- February 2018: Colorectal Cancer resulting in bowel resection with large loop ileostomy
- July 2020: Cancer progressed and gentleman referred to palliative care.

Problems Experienced

- Both limbs of loop ileostomy prolapsed which made it difficult to view the peristomal skin to apply a seal and pouch.

Nurse Advice

Due to the impaired view of the loop ileostomy, an eakin **Cohesive**[®] stomawrap was suggested to facilitate easier application. The gentleman was previously using an eakin **Cohesive**[®] small to protect peristomal skin.

Due to the prolapsed stoma, the aperture of the pouch was cut slightly larger for easier application - leaving gaps between the baseplate and stoma. The eakin **Cohesive**[®] stomawrap filled these gaps, fitting securely under the baseplate.

Solution with eakin **Cohesive**[®] stomawrap

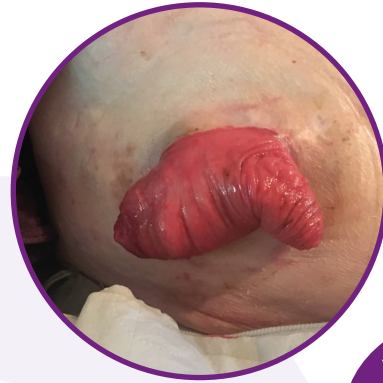
Skin: No leaks occurred and skin condition remained excellent.

Stoma Management: Using the eakin **Cohesive**[®] stomawrap allowed the gentleman to easily attach the two ends of the product above his stoma, creating a **secure fit by touch alone.**

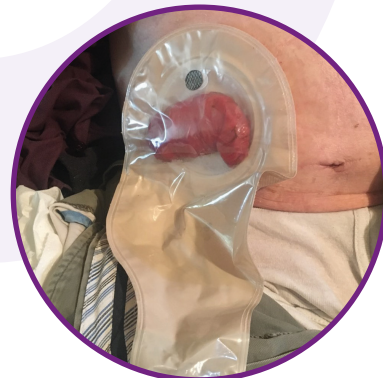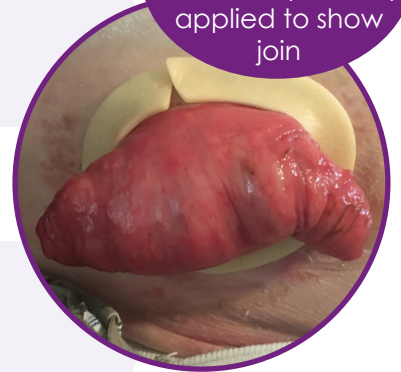Bigger Life: Independence in stoma management initially meant no reliance on others for assistance and continuation of his normal routine.

Ongoing care

- As the gentleman's condition deteriorated he relied on a carer for support and assistance with his stoma care.
- The carer had minimal stoma care experience, however found the application of eakin **Cohesive**[®] stomawrap simple.
- Skin health remained excellent.



For visual purposes, eakin **Cohesive**[®] Stomawrap loosely applied to show join



eakin.eu

Case study submitted by:
Kate Slattery
Community Stoma Care Nurse, Ireland