

# eakin **Cohesive**® large for sensitive damaged peristomal skin

## Background

- 44 year old obese gentleman with fair skin and red hair.
- PMH intellectually impaired.
- Diagnosis of IBD – severe colitis, unsuccessfully medically managed, resulting in Total Colectomy.
- End ileostomy formed.

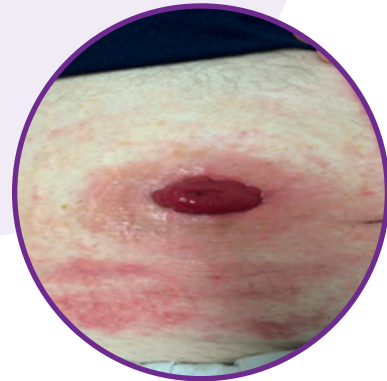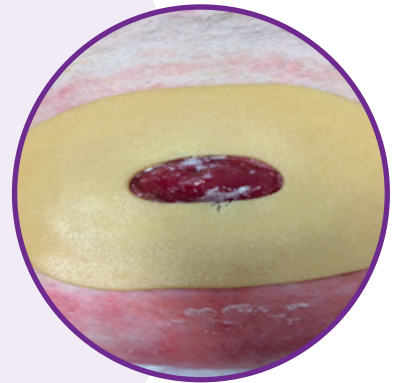
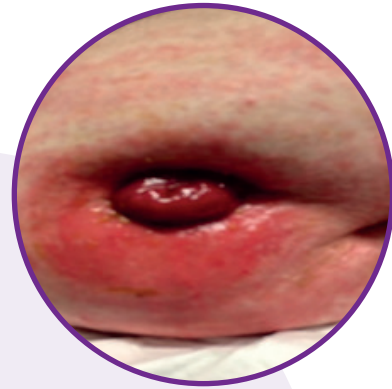
## Problems Experienced

- Abdomen was tight and distended meaning the stoma was under skin folds.
- Sensitive skin with a number of allergies including to adhesive dressings.
- Leaks, effluent contact dermatitis and unskilled carers resulted in severely eroded peristomal skin.

## Nurse Advice

The eroded skin extended to the outer edge of the pouch baseplate and therefore a larger area of peristomal skin required protection.

eakin **Cohesive**® large seal was introduced due to size of the seal and skin friendly properties.



## Solution with eakin **Cohesive**® large

**Skin:** Effluent contact dermatitis is resolving with the large seal coming into direct contact with the peristomal skin.

**Stoma Management:** Both the gentleman and carers have been upskilled in stoma management and the issues experienced have been resolved.

**Bigger Life:** Gentleman commented:

*“I feel so much happier now that I do not have sore skin and leaks and I can go back to my painting classes without worrying that I am going to make a mess everywhere and smell terrible.”*